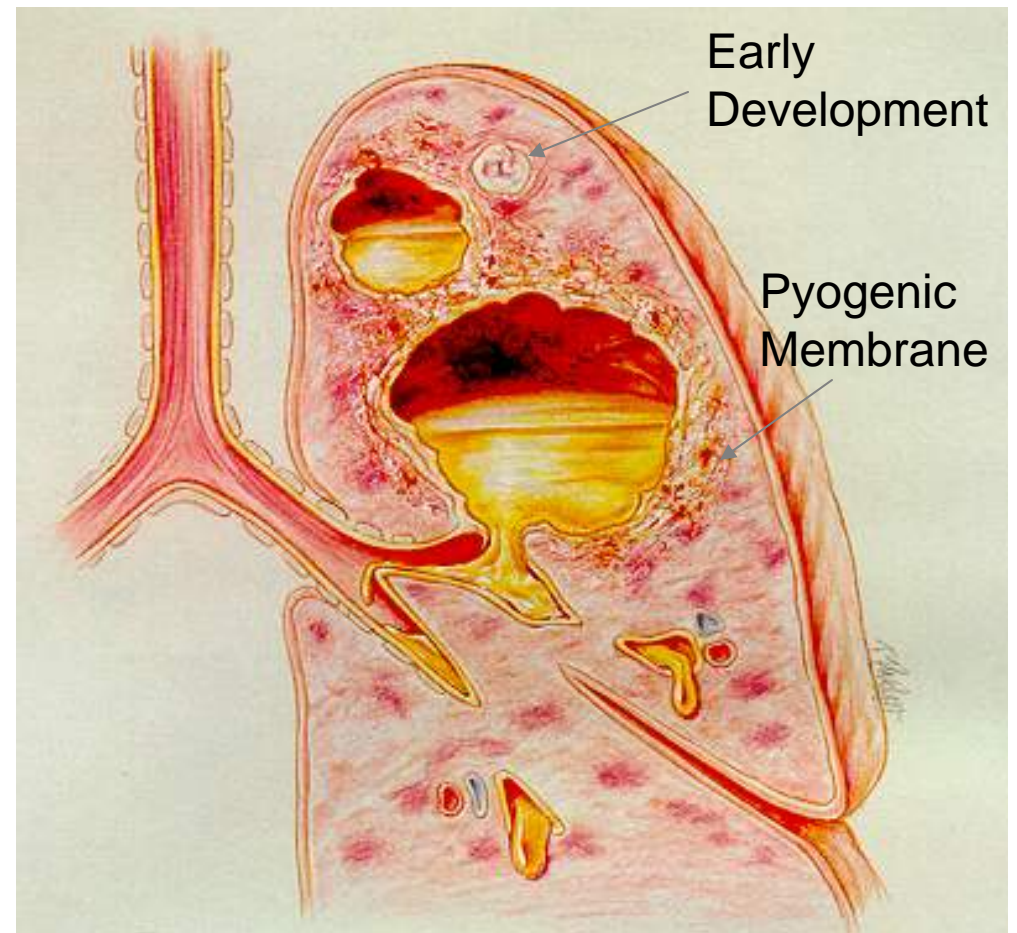


Lung Abscess

Ray Hernandez, RRT, BA

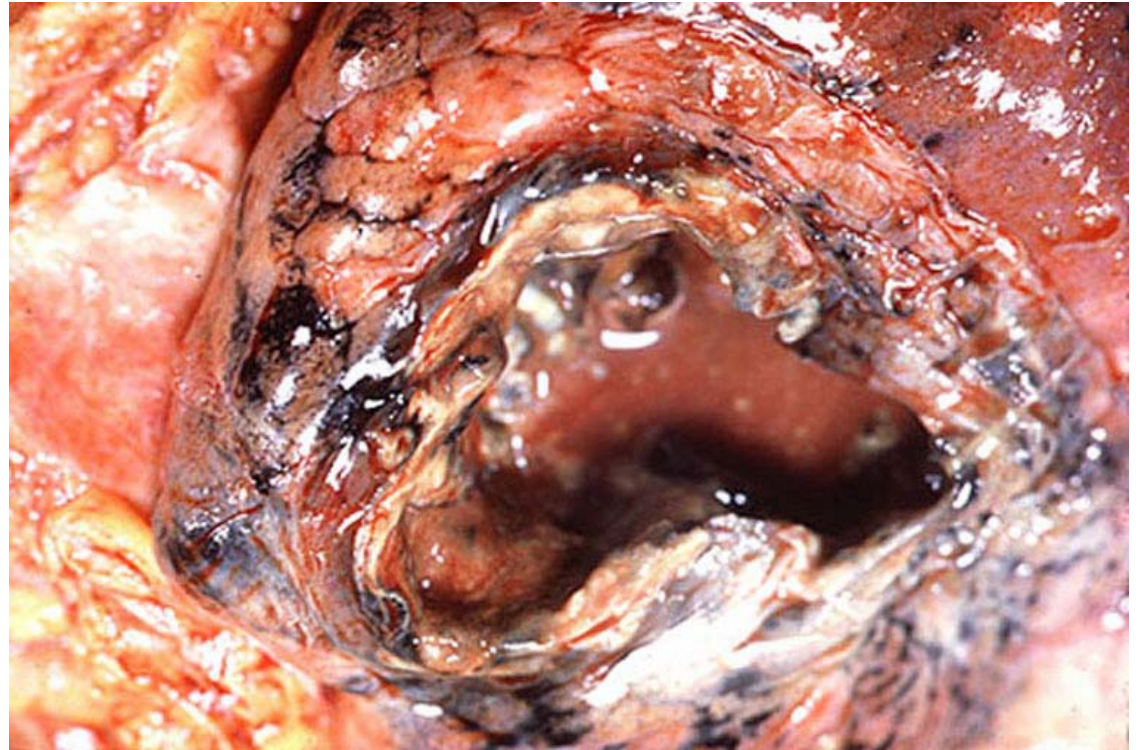
Lung Abscess

- Localized infection
- Air-fluid filled cavity
 - WBCs
 - Protein
 - Tissue Debris
- Pyogenic Membrane



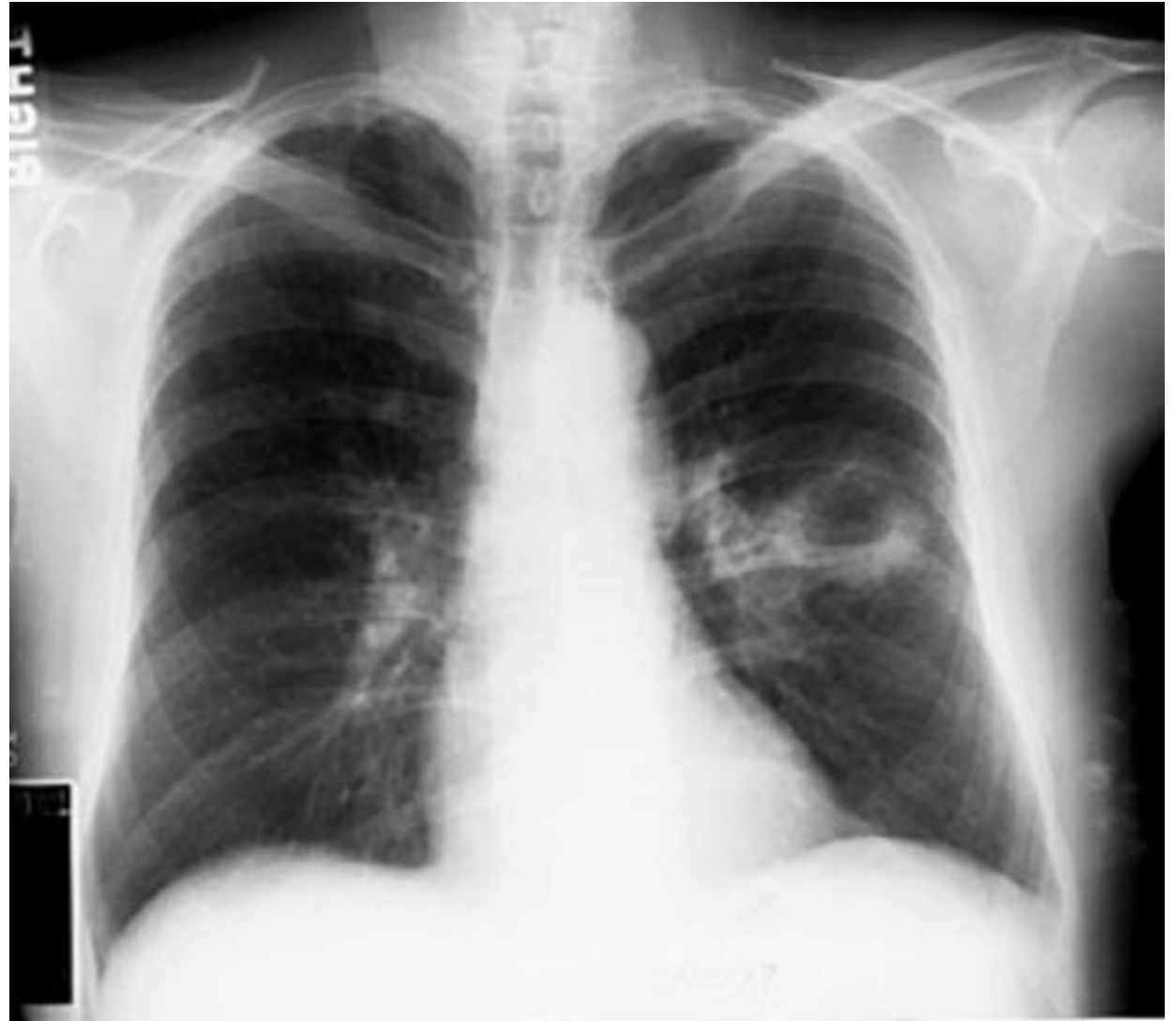Etiology

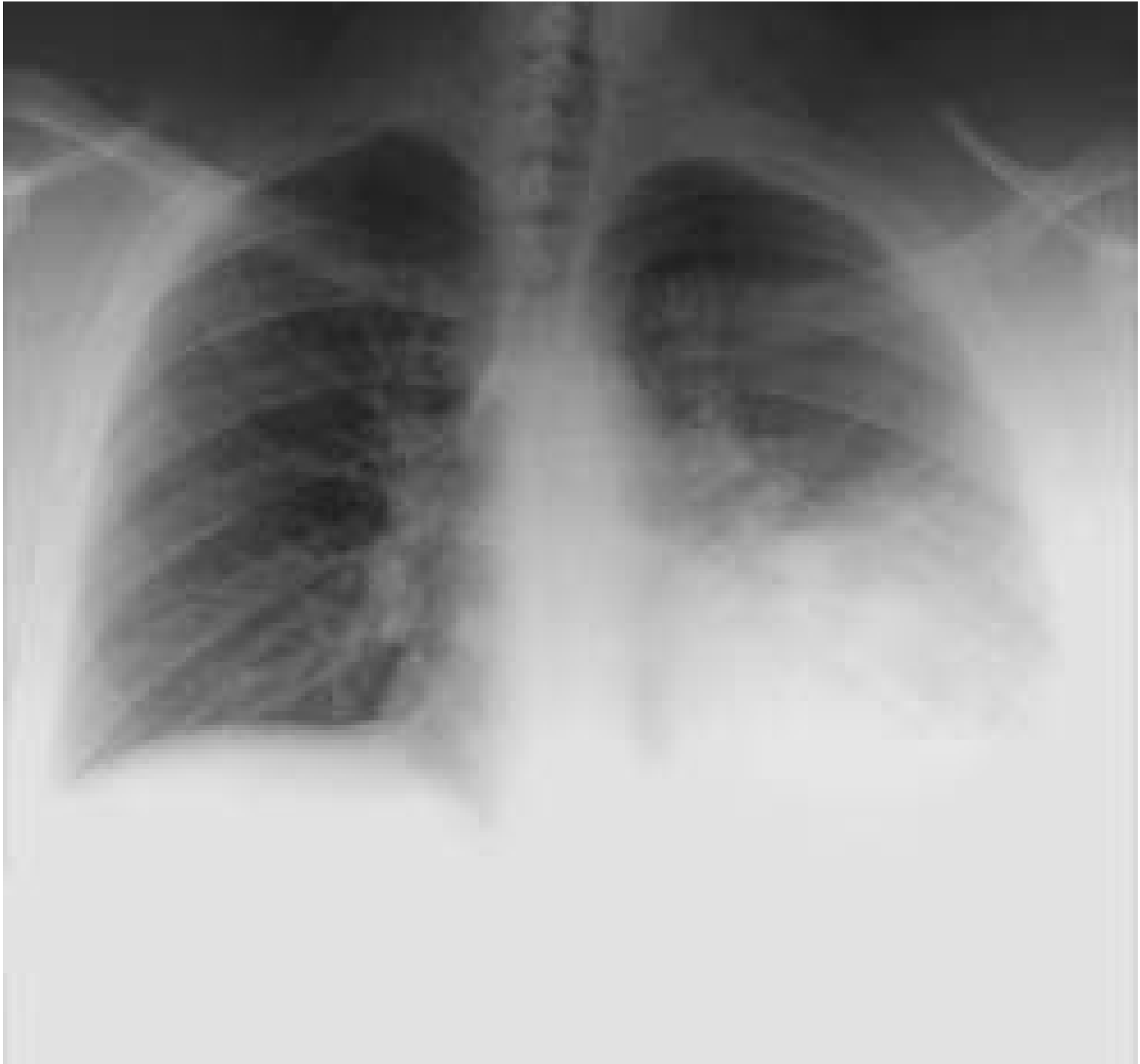- Aspiration
 - Staphylococcal aureus
 - Anaerobic organisms
- Alcohol Abuse
- Seizure disorder
- CVA
- Head trauma
- General Anesthesia
- Secondary cavitating infection



Radiologic Findings

- Increased opacity
 - Consolidation
 - Atelectasis
- Cavity formation
 - Air-fluid
- Fibrosis and calcification
- Pleural effusion





Radiologic Finding CT

